

# HEMORRHAGIC COLITIS ASSOCIATED WITH BABESIOSIS IN A COCKER SPANIEL DOG: A CASE REPORT

B. Subhash Chandra<sup>1</sup>, A. Abiramy @Prabavathy<sup>2</sup>, P. Vijayalakshmi<sup>3</sup>,  
D. Selvi<sup>2</sup>, K. Rajkumar<sup>2</sup> and B. Subramanian<sup>1</sup>

<sup>1</sup>M.V.Sc. Student, <sup>2</sup>Assistant Professor, <sup>3</sup>Associate Professor and Incharge; Department of Veterinary Medicine; Teaching Veterinary Clinical Campus; Rajiv Gandhi Institute of Veterinary Education and Research, Mettupalayam, Puducherry -9.

[Received: 29.8.2017; Accepted: 03.4.2018]  
{DOI 10.29005/IJCP.2018. 10.1.018-019}

A three years old Cocker Spaniel dog was presented to TVCC, RIVER with the history of tenesmus, pyrexia, blood tinged mucoid faeces, inappetance and gradual weight loss for past one month and was diagnosed with hemorrhagic colitis by colonoscopy and a concurrent infection of *Babesia gibsoni* by peripheral blood smear examination. The dog was treated with Diminazineaceturate, Azithromycin and Metronidazole combination along with the supportive fluid therapy. Gradual reduction in hematochezia and marked improvement in appetite was noticed along with absence of *Babesia gibsoni* organisms in the subsequent blood smear examination.

**Keywords:** *Babesia gibsoni*, Babesiosis, Colonoscopy, Hematochezia, Hemorrhagic colitis.

Chronic colitis is a common syndrome recognized in dogs, characterized by intermittent diarrhea with hematochezia and tenesmus, weight loss, occasional vomiting, and abdominal pain (Greene, 1998). Canine babesiosis is caused by the blood protozoans of the genus *Babesia* (Ayoob *et al.*, 2010) that infect a variety of animals and humans globally (Beugnet *et al.*, 2015). Several species of *Babesia* have been documented to infect dogs but, only *Babesia canis* and *Babesia gibsoni* are found to be present in Asia (Ayoob *et al.*, 2010). *B. gibsoni* infection was found frequently in companion dogs and causes immune mediated anemia and thrombocytopenia along with leukocytic changes, influenced by stress, systemic inflammation and bone marrow stimulation (Lai *et al.*, 2011)

Colonoscopy is a technique routinely used for examination of the rectum and large intestine. It can be performed using either a rigid proctoscope or flexible gastro intestinal endoscope.

## Case History and Observations

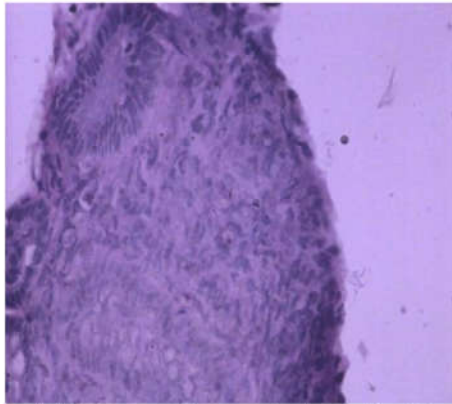
A three years old Cocker Spaniel dog was presented with the history of tenesmus, blood tinged mucoid faeces and gradual weight loss for past one month. Clinical examination of the dog revealed anaemia, pyrexia (104.1°F), lymphadenomegaly,

tachycardia and signs of dehydration. Fecal examinations were negative for parasitic eggs or oocysts. The dog was subjected for colonoscopy in sternal recumbency and hemorrhages were noticed in the descending colon (Fig.1). A Pinch biopsy was collected from the mucous membrane of colon. The histopathological examination of the pinch biopsy revealed mild crypt hyperplasia (Fig.2). Hematological examination revealed neutrophilia and presence of *Babesia gibsoni* organisms. The condition was diagnosed as hemorrhagic colitis associated with *Babesia gibsoni* infection.

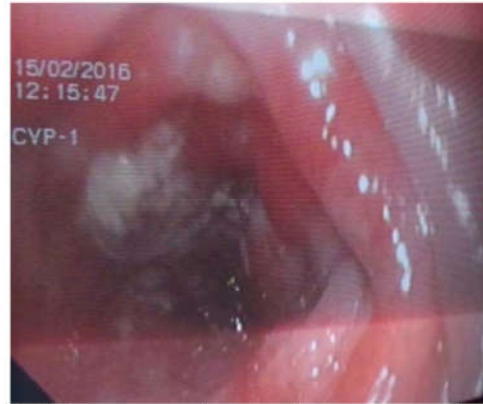## Treatment and Discussion

The dog was treated with single dose of Inj. Diminazineaceturate @3.5 mg/kg deep IM, Inj. Metronidazole @30 mg/kg bid IV for 5 days, along with Tab. Azithromycin @10 mg/kg sid PO for 15 days, Syrup Sucralfate and supportive fluid therapy was given with Dextrose Normal Saline and Ringer's Lactate.

The dog suffered from hemorrhagic colitis and the cause has been postulated as immunosuppression. Chronic colitis does not appear to be associated with primary bacterial pathogen but probably results from stress, debilitation, or immunosuppression as also mentioned by Greene (1998). A pinch biopsy was taken from colon using colonoscopy and was subjected for histopathology, which revealed mild crypt hyperplasia. Hyperplasia



**Fig. 1.** Mild crypt hyperplasia noticed by histopathological examination of pinch biopsy of colon



**Fig. 2.** Colonoscopy showing hemorrhages in the colon

of crypts was one of the earliest histopathological changes seen in canine colitis which was noticed in the present case.

Compromised immunity appears to be a risk factor for *Babesia* infection as the disease develops when the immune system is no longer can control the level of parasitemia resulting in developing persistent infections as also reported by Sikorski *et al.* (2010). The dog was anaemic since *B. gibsoni* infection causes acute regenerative haemolytic anemia. Also, the severity of the disease primarily depends on immune status and age of the animal. Hence stress and immune compromise probably would have paved a way for acquiring infection with *Babesia gibsoni* along with colitis.

The dog was treated with Inj. Diminazineaceturate which binds to and inhibits parasite DNA synthesis, thus preventing the growth of organisms. Inj. Metronidazole was administered to prevent bacterial growth in the intestine. Tab. Azithromycin was given which controls protozoal development by inhibiting the protein synthesis and is effective against the organisms. Sucralfate syrup was administered as cyto-protective drug and supportive fluid therapy was given with Dextrose Normal Saline and Ringer's Lactate to correct the electrolyte balance.

There was gradual reduction in hematochezia and marked improvement in appetite after the treatment and the subsequent blood smear examination conducted after one month of treatment was negative for *Babesia gibsoni*.

#### References

- Ayoob, A.L., Hackner, S.G. and Prittie, J. (2010). Clinical management of canine babesiosis. *J. Vet. Emer. and Critical Care*, **20**: 77–89.
- Beugnet, F. and Moreau, Y. (2015). Babesiosis. *Rev. Sci. Tech. Off. Int. Epiz.*, **34**: 627–639.
- Greene, C.E. (1998). *Infectious Diseases of the Dog and Cat*, 2<sup>nd</sup> edn. MO: WB Saunders Co., St Louis, U.S.A. Pp: 609–610.
- Laia, S. and Baneth, G., (2011). Babesiosis in dogs and cats—Expanding parasitological and clinical spectra; *Vet. Parasitol.*, **181**: 48–60.
- Sikorski, L.E., Birkenheuer, A.J., Holowaychuk, M.K., McCleary-Wheeler, A.L., Davis, J.M. and Littman, M.P. (2010). Babesiosis Caused by a Large *Babesia* Species in 7 Immunocompromised Dogs, *J. Vet. Intern. Med.*, **24**: 127–131.