

VAGINAL AND UTERINE LEIOMYOMA IN A FEMALE DOG: A CASE REPORT

K. Mohammed Arif Basha¹, K.M. Srinivasa Murthy², L. Ranganath³ and Narsimha Murthy⁴
¹M.V.Sc. Student, ²Assistant Professor, ³Professor & Head, Department of Surgery and Radiology; ⁴Assistant Professor, Department of Gynaecology and Obstetrics; Veterinary College; KVAFSU, Bangalore-560024.

[Received: 26.10.2017; Accepted: 01.5.2018]

{DOI 10.29005/IJCP.2018. 10.1.080-081}

An eight year old female German shepherd dog was presented with a history of progressive abdominal distension, dyschezia and dribbling of urine and discharge of pus from vagina since one week. Per rectal examination with a lubricated fingered glove revealed a large mass in ventral pelvic cavity extending into the abdomen. Mass could also be felt on abdominal palpation. No history of breeding was found. Ultrasound scanning of abdomen revealed an anechoic urinary bladder containing fluid and a relatively hyperechoic large mass adhered to bladder. Only after exploratory laparotomy it was confirmed that large mass firmly pressing urinary bladder was a uterine leiomyoma adhered to the bladder. One more separate mass pre cervically adhered to vagina was found which was also surgically excised. Histopathological examination confirmed both the masses as Leiomyoma. A case of vaginal and uterine leiomyoma with pus at the centre of the mass in a bitch and its successful surgical management is reported.

Keywords: Bitch, Leiomyoma, Uterus, Vagina.

Leiomyoma is a tumor of smooth muscle cells that may arise in any organ with connective tissue and mesenchymal component. Neoplasm of female tubular genitalia account for 3% of all canine tumors, of these 85-90% occur in vagina and vulva (Ashley, 1978). Leiomyoma uteri (fibroid) are rare in a bitch (Suresh Kumar *et al.*, 1995). Uterine tumours can obstruct the cervix and may cause pyometra (Fossum, 2002). Sumathi *et al.*, (2016) reported diagnosis of leiomyoma by ultrasonography and its surgical management. Prashanth *et al.*, (2015) reported vaginal leiomyoma as a cause of obstructive dystocia in a bitch.

An eight year old female German shepherd dog was presented to Veterinary

College Hospital; Hebbal, Bangalore with a history of dyschezia and dribbling of urine and discharge of pus from vagina since one week. On per rectal examination with a gloved finger a mass was palpated at ventral abdomen, cranial to pelvis. The animal had a temperature of 102.4°F whereas, pulse and heart rates were normal. Ultrasound scanning of abdomen revealed an anechoic pouch containing fluid and an acoustic enhanced hyperechoic large mass below the fluid interface in the pelvic cavity extended into the abdomen. On catheterization urine was clear but pus from the cervical opening was noticed. It was decided to perform an exploratory laparotomy.

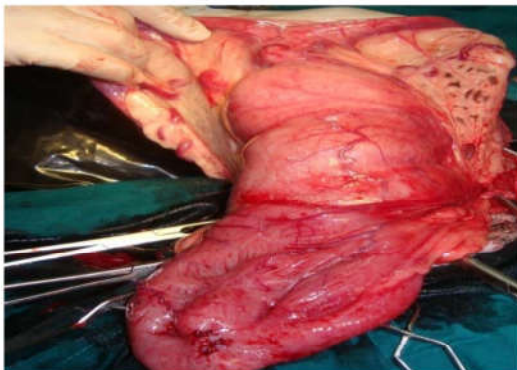


Fig-2: Uterine mass with pyometra adhered to the bladder

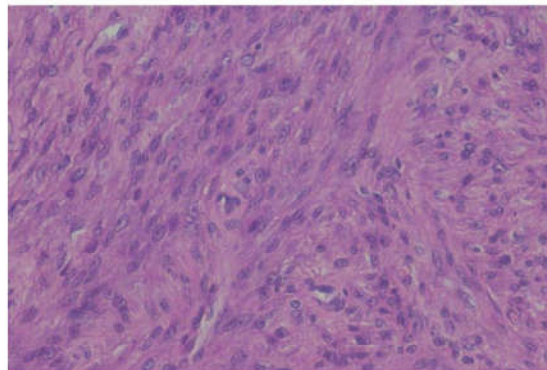


Fig-4: Histopathological image showing spindle shaped proliferating cells with elliptical vesicular basophilic nucleus

Dog was prepared for aseptic surgery and premedicated with Atropine Sulphate @ 0.02 mg/kg body weight i/m, butorphanol 0.2mg/kg body weight i/v and Triflupromazine hydrochloride @ 1mg/kg body weight intra venously. Anesthesia was induced with Thiopentone sodium at dose rate of 12.5 mg/kg body weight i/v and maintained with 2% Isoflurane. On caudal midline exploratory laparotomy an extraluminal uterine mass with a pouch containing pus adhering to the bladder was noticed (Fig-1). The adhesion of the mass with the bladder and intestine was released and ovariohysterectomy was performed as per the standard procedure along with uterine mass. One more mass protruding out of the vaginal passage was found which also surgically excised. Abdominal cavity was lavaged with warm normal saline. The ventral abdominal wound and subcutaneous tissue were closed routinely followed by skin closure. From the next day after surgery animal was able to void urine normally and pass feces without difficulty. Post operatively Ceftriaxone (20mg/kg) was given intra muscularly for 7 days. The animal was maintained by parenteral administration of RL and Dextrose 5% daily for three days. Sutures were removed on tenth post operative day and animal recovered uneventfully.

Grossly the uterine mass was about 7 x 13 cm sized and hard in consistency with a

pouch filled with pus at the centre of the mass. Vaginal mass was 3.5 x 5 cm in size and also pus filled. The samples of each masses were sent for histopathological examination which showed spindle shaped proliferating cells of smooth muscle in origin with elongated cigar shaped basophilic nucleus with abundant eosinophilic cytoplasm. The proliferating cells appeared in radiating pattern, suggestive of Leiomyoma for both the masses (Fig-2).

References

- Ashley, D.J.B. (1978). *Evan's histological appearances of tumours*. 3rd edn., Vol. 1. New York: Longman Co Ltd., New York, U.S.A. Pp. 705-723.
- Fossum, T.W. (2002). *Small Animal Surgery*, 2nd edn., Mosby, Inc, An Elsevier Science Company, St.Louis, Missouri, U.S.A. Pp. 638.
- Prashanth, C., Sudha, G., Jayakumar, C. and Yugandhar, M. (2015). Vaginal leiomyoma as a cause of obstructive dystocia in a bitch. *Ind. J. of Canine Practice*, 7(1): 21-24.
- Sumathi, D., Venkateshan, M. and Shivashankar, R. (2016). Diagnosis and management of Leiomyoma in dog. *Intas Polivet*, 17(1): 198-199.
- Suresh Kumar, R.V., Ramakrishna, O. and Sreeraman, P.K. (1995). Leiomyoma uteri in a bitch. *Can. Vet. J.*, 36: 185.