

# ELECTROCARDIOGRAPHIC EVALUATION IN UREMIC DOGS

Ashna Annette Aipe<sup>1</sup>, Usha Narayana Pillai<sup>2</sup>, P.C Alex<sup>3</sup>, S. Ajithkumar<sup>4</sup>, R. Uma<sup>5</sup>  
and M. Madhavanunni<sup>5</sup>

<sup>1</sup>MVSc Scholar, <sup>2</sup>Associate Professor, <sup>3</sup>Professor and Head, <sup>4</sup>Professor and <sup>5</sup>Assistant Professor,  
Deptt. of Clinical Veterinary Medicine, College of Veterinary & Animal Sciences, Mannuthy, Thrissur, Kerala.

[Received: 24.5.2014; Accepted: 26.11.2014]

Electrocardiography was helpful in diagnosing cardiac diseases, differentiation of non specific disease that caused fatigue, fever, lethargy, collapse or seizures and also while monitoring anaesthesia and surgery. The electrocardiographic patterns of twelve animals having the clinical signs of uremia and serum creatinine more than 4 mg/dL were studied and abnormalities were detected.

## Materials and Methods

Twelve dogs of brought to Teaching Veterinary Clinical Complex, Mannuthy and University Veterinary Hospital during February 2013- 2014 with clinical signs suggestive of uremia *viz* anorexia, polyuria, polydypsia, lethargy, weight loss, vomiting and ulceration of mucous membranes and biochemical changes of serum creatinine more than 4 mg/dL and blood urea nitrogen more than 90 mg/dL were selected and utilized for the present study.

Electrocardiogram of the animals were recorded using BPL- CARDIART – 6108T (2011 FROST & SULLIVAN) ECG

machine as per the procedure of Goodwin (2001) and Martin (2002) with paper speed of 25 mm per second and sensitivity of 1 mV = 10 mm.

## Results and Discussion

The normal electrocardiogram in apparently healthy animals (Fig: 1). The electrocardiographic changes observed in the study were spiked Twaves ( Fig:2), sinus arrest (Fig:3), arrhythmias like VPC (Fig:4) and ST depression (Fig:5).

These electrocardiographic changes might be due to chronic left heart strain, myocardial changes due to coronary artery disease, diffuse pericarditis, hyperkalaemia and hypocalcemia. In advanced stages of potassium intoxication various forms of ventricular arrhythmia were observed (Langendorf and Pirani, 1947, Somerville, 1951 and Langston, 2008)

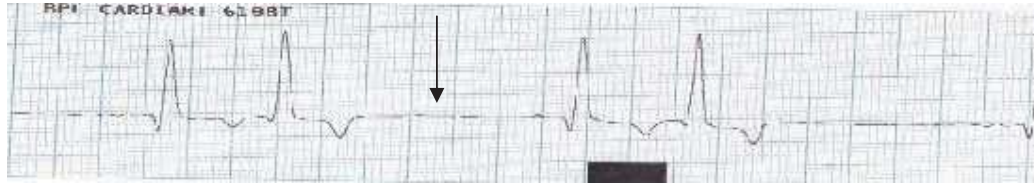
Hence electrocardiography can be used as a diagnostic tool in detecting the electrolyte changes in uremic dogs and for further medical management.



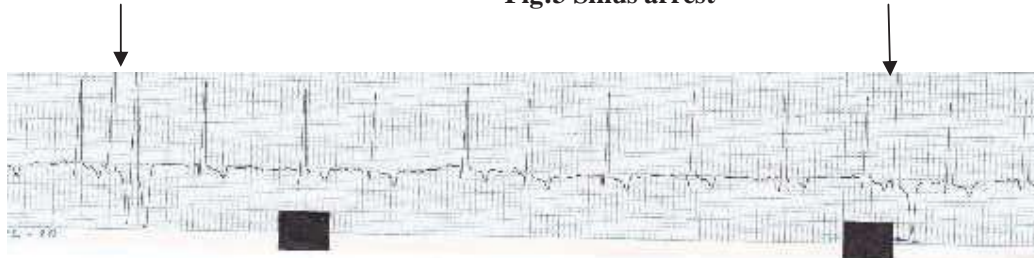
Fig:1 Normal E.C.G in healthy animals

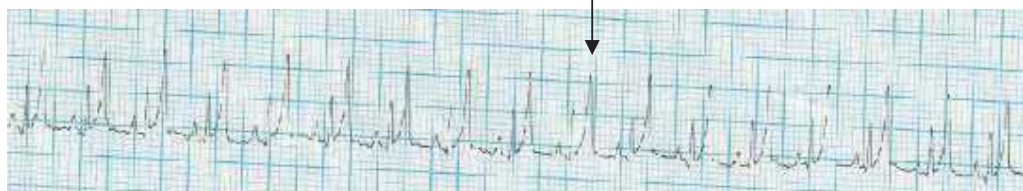

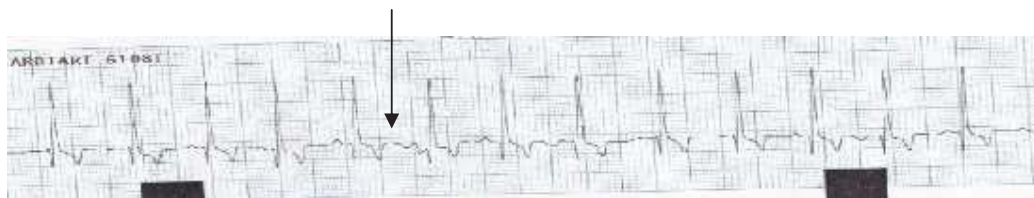Fig:2 Spiked T waves



**Fig:3 Sinus arrest**



**Fig:4 Ventricular Premature Complex (VPC)**



**Fig: 5 ST depression**

### References

- Goodwin, J.K. 2001. Electrocardiography. *Manual of Canine and Feline Cardiology*. (eds. Tilley, L.P. and Goodwin, J.K.) Third edition. W.B. Saunders Co., Philadelphia, Pp. 43-70.
- Langendorf, R. and Pirani, C.L. 1947. The heart in uremia: An electrocardiographic and pathologic study. *American Heart Journal*. **33**: 282-307
- Martin, M. 2002. ECG interpretation in small animals. 1. Understanding the electricity of the heart. *In Practice*. **24**:114-123.
- Langston, C. 2008. Managing fluid and electrolyte disorders in renal failure. *Vet.Clin. Small Anim*. **38** : 677-697.
- Somerville, W. 1951. The effect of potassium and calcium on the electrocardiogram. *Postgrad Med J*. **27**: 296-302.