

ECTOPIC TESTIS AND ITS SURGICAL REMOVAL IN A SPITZ DOG

A.K.Sharma*, Sanjit Kumar, Kumari Chandrakala, Laxmi Kumari and Praveen Kumar

*Assistant Professor, Department of Surgery and Radiology, College of Veterinary Sciences and Animal Husbandry, Birsa Agricultural University, Kanke, Ranchi-834006 (Jharkhand).

[Received: 23.8.2015; Accepted: 04.4.2016]

An ectopic testis is the deviations of testis from the normal path of descend after it has emerged through the external inguinal ring. Testicular descend usually occurs at birth, although it may occur normally at any time up to six months of age (Dunn *et al.*, 1968). Ectopic testis may be found either in the superficial inguinal pouch which lies anterior to the external oblique apponeurosis or in the perineum or at the root of the penis or in the femoral canal. Often abdominal ectopic testes are more common than inguinal ectopic tests (Morgan, *et al.*, 2003). The above mentioned case possessed an enlarged ectopic testis located lateral to penis subcutaneously and its surgical removal.

A 5 year old Spitz male dog was presented with history of swelling sized 4x5 cm on the right lateral aspect of penis. There was no complaint of ill health in respect of feeding, defaecation, urination, pain etc. Clinically the dog was active and alert.

Physical examination revealed that both testes were ectopically presented subcutaneously lateral to penis. The left testis was atrophied. The enlarged testis was hard in consistency and painless to touch. The case was diagnosed to be an ectopic testis warranting surgical excision.

The dog was anaesthetized with Atropine sulphate @0.04 mg/kg bwt, Xylazine Hcl @1 mg/kg bwt and ketamine Hcl@5 mg/kg bwt and the site was prepared aseptically. A longitudinal incision was given on the periphery of swelled portion towards the side of penile portion. The testis was separated by blunt dissection with finger and removed through a linear incision after double ligation of the spermatic cord with chromic cat gut No. 0 (Fig-1). The left testis was also removed by same procedure (Fig.2). The subcutaneous tissues were sutured with absorbable suture materials and skin with nylon by cross mattress pattern.

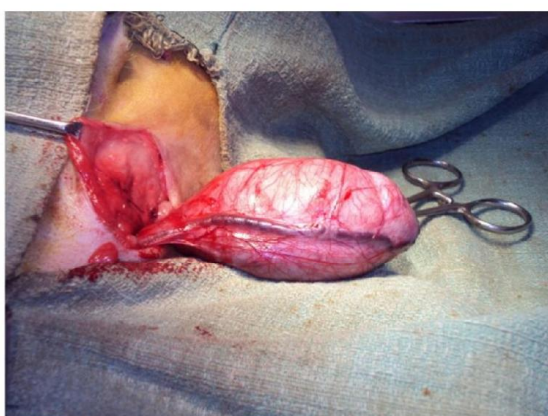

Fig.1: Exposed ectopic testis (right side) through surgical intervention.

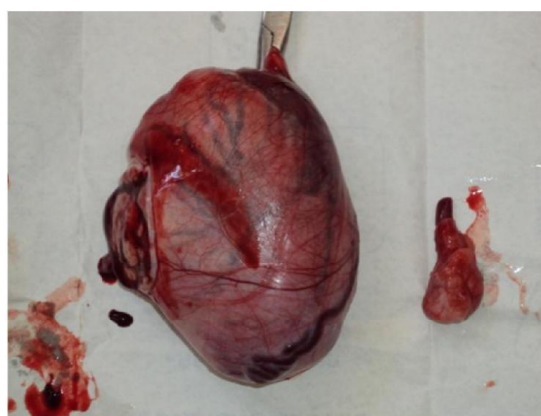


Fig. 2: Removed both testes after surgery

Post – operatively, the dog was given Cefpet oral suspension @8-10 mg/kg bwt for 5 days and Melonex oral suspension @1ml for 2 days. The surgical wound was routinely

dressed with povidone iodine (5%). The sutures were removed on 10th day post operatively. The dog made uneventful recovery 10th day post- operatively.

Ectopic testis can occur in the subcutaneous tissue above the inguinal canal (superficial inguinal pouch), in the perineum, lateral to scrotum and in the femoral region and are often palpated as also reported by Hutcheson *et al.* (2000). In the present case, the location of both testes was found to be different as the testes were found in the subcutaneously lateral to the penis. Chihuahua, Miniature Schnauzer, Pomeranian, Poodle, Short haired sheep dog, Siberian Husky and Yorkshire Terrier are reported to be commonly affected breeds of dog as also reported by Morgan *et al.* (2003).

References

- Dunn, M.L., Foster, W.J. and Goddard, K.M. (1968). Cryptorchidism in dogs: a clinical survey. *J. Am. Anim. Hosp. Assoc.*; **4**: 180.
- Hutcheson, J.C., Snyder, H.M. and Zuniga, Z.V. (2000). The Ectopic Testis: Another form of undescended Testis. *J. Urol.*; **163**: 961-963.
- Morgan, R.V., Bright, R.M. and Swartout, M.S. (2003). Hand book of Small Animal Practice. 4th Edn., Saunders, Philadelphia. Pp. 94-96.