

AXIAL OSTEOSARCOMA IN A LABRADOR DOG

N. Sumiran¹, S. Bharathi², L. Siva Sudarshan² and G. Kamalakar¹

¹Assistant Professor, Department of Veterinary Surgery and Radiology, ²Assistant Professor Teaching Veterinary Clinical Complex; College of Veterinary Science, Sri Venkateswara Veterinary University, Proddatur- 516 360 (A.P.).

[Received: 13.6.2016; Accepted: 06.3.2017]

Osteosarcoma is a mesenchymal malignant tumor arising from osteoblasts. Oral and maxillofacial osteosarcomas are categorised under axial or flat bone osteosarcomas and these tumors are locally aggressive with lower metastatic potential when compared with other osteosarcomas (Farcas *et al.*, 2012). Though the osteosarcoma of the mandible and maxilla is the fourth most common non-odontogenic tumor of oral cavity in dogs (Verstraete, 2005) accounting for 12.4% of all osteosarcomas and 85% of primary bone tumors in dogs (Farcas *et al.*, 2012), reports on incidence of axial osteosarcomas are rarely seen. It is commonly seen in large and giant breeds with high predisposition towards increasing weight and height (Pool *et al.*, 1990). Clinical signs like pain, swelling and discomfort associated with opening or closing the mouth are due to expansive mass and tissue destruction. Dickerson *et al.*, (2001) reported that chemotherapy would increase survival rate for dogs if primary tumor is adequately controlled with surgery or

definitive radiation therapy or both. Hence the present article was aimed to report the rare case of axial osteosarcoma in a Labrador dog.

A male Labrador dog was presented to the College of Veterinary Science, Proddatur with the swelling of 8cm diameter approximately beneath the left eye along with difficulty in mastication (Fig.1). History revealed that initially it was small in size which was neglected and which further resulted in sudden increased in size covering the entire eyeball affecting its vision. Radiography revealed soft tissue swelling with brush border appearance on maxilla but without (Fig.2). FNAC was taken from 3 different sites of which one from buccal mucosal surface and two were taken on external swelling which revealed malignant cells with increased number of neutrophils. Later it was confirmed as osteosarcoma in histopathology of biopsy sample. Knowing the complications the owner did not agree for its radical therapies. However to place it on record the condition is reported.

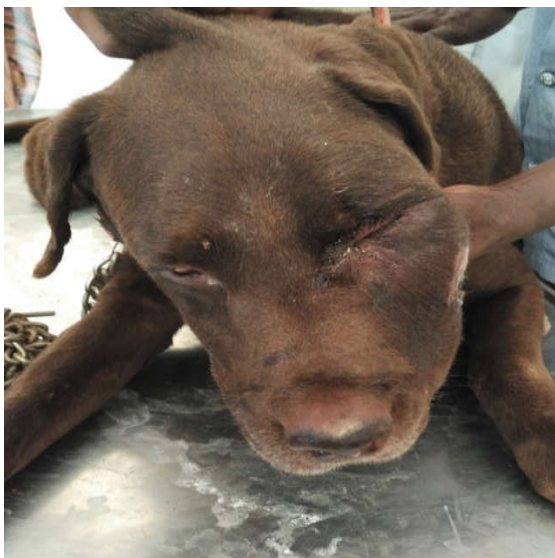

Fig.1: Huge swelling beneath the eye enclosing the eyeball

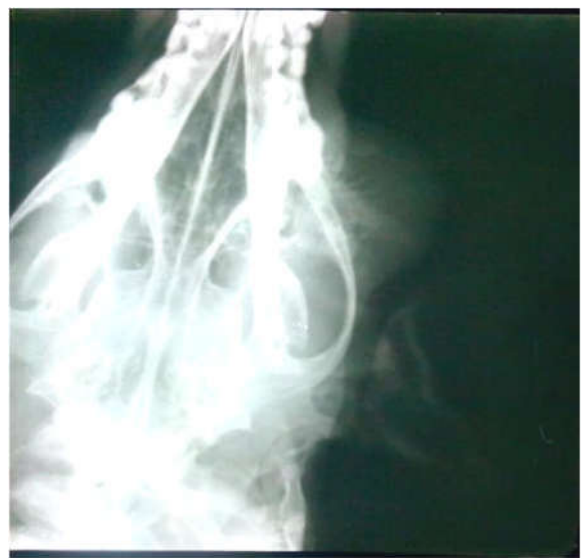


Fig. 3.Radiograph showing soft tissue swelling along with brush border appearance of maxilla

References

- Dickerson, M.E., Page, R.L., La Due, T.A., Hauck, M.L., Thrall, DE., Stebbins, M.E. and Price, G.S. (2001). Retrospective analysis of axial skeleton osteosarcoma in 22 large breed dogs. . *Vet. Intern. Med.*, **15**: 120-124.
- Farcas, N. Arzi, B. and Verstraete, F.J.M. (2012). Oral and maxillofacial osteosarcoma in dogs: a review. *Vet. Comp. Oncol.*, **12(3)**: 169-180.
- Pool, R.R. (1990). Tumors of bone and cartilage. In Moulton, J.E. Tumors in domestic animals 2nd Edn. Berkeley: University California Press, U.S.A. Pp.89-147.
- Verstraete, F.J. (2005). Mandibulectomy and maxillectomy. *Vet. Clin. North Am. Small Anim. Pract.*, **35**: 1009-1039.

ATTENTION

Hereby attention of all the Life Members of the I.S.A.C.P. is drawn for updating their addresses. If any body is not getting the News Letters and other Communications regularly, is requested to update the ISACP with Latest Address, E-mail I.D., Telephone No. and Cell No. to the Society's Regd. Office – Indian Society for Advancement of Canine Practice, 21/5, Sector – 21, Indiranagar, Lucknow – 226 016; India.

E-mail: isacp.newsletter@gmail.com; sugandha31@rediffmail.com